

# IMMEDIATE OCCLUSAL LOADING™ (IOL™) OF DENTAL IMPLANTS: Predictable Results Through DIEM™ Guidelines

*Richard J. Lazzara, DMD, MScD\**

*Tiziano Testori, MD, DDS†*

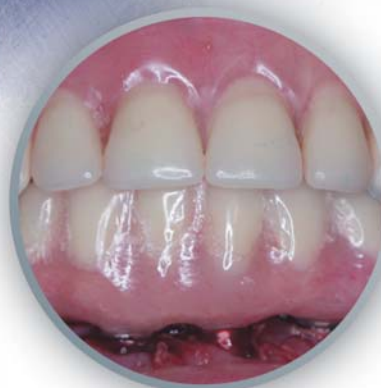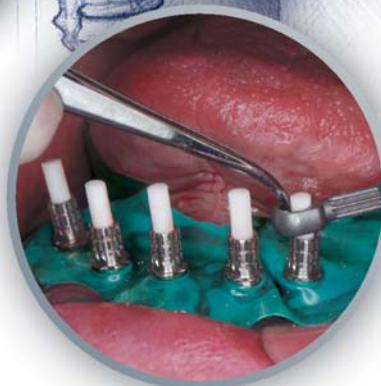
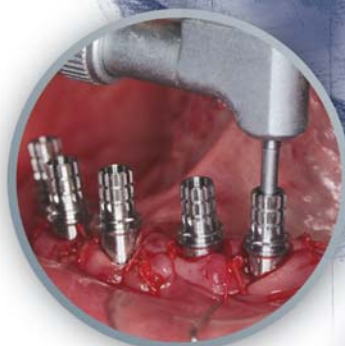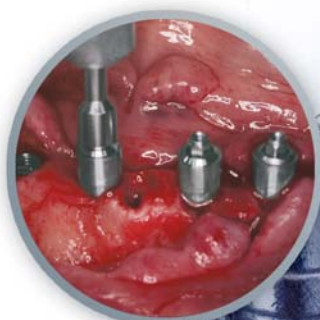*Alan Meltzer, DDS, MScD‡*

*Craig Misch, DDS, MDS§*


*Stephan Porter, DDS, MSD, MS||*

*Robert del Castillo, DMD\*\**

*Ronnie J. Goené, DDS††*



A Supplement to a Montage Media Publication

Supported by an educational grant from 

## Maturation of the Immediate Loading Concept:

*Dennis P. Tarnow, DDS\**

In recent years, the immediate loading of dental implants has become more accepted as a standard protocol for the treatment of the fully edentulous mandible. The pioneers in implant dentistry often tried this technique but only achieved mixed success. One of the main reasons for the failure of these early attempts was the lack of understanding of the biological and mechanical principles that we now know are necessary for clinical success.



Professor and Chairman  
Department of Implant Dentistry  
New York University  
College of Dentistry



Dental implants that are immediately loaded should be stable after insertion, and they should be rigidly splinted around the curvature of the arch. In addition, the provisional prosthesis should not be disturbed (if possible) during the healing process that occurs approximately two months after placement. These simple guidelines have allowed for the predictable treatment of many patients who would otherwise have had to wear their dentures during the healing period or even go without them during the initial post-operative period.

The following monograph is another step in the maturation of the immediate loading technique. The authors have outlined their technique for predictable loading of the edentulous mandible as well as the use of new components that make the procedure faster and more user-friendly for the patient and the treating team. They are to be complimented for taking on this project and using an evidence-based approach to support their techniques and definitions.

# IMMEDIATE OCCLUSAL LOADING™ (IOL™) OF DENTAL IMPLANTS: Predictable Results Through DIEM™ Guidelines

*Richard J. Lazzara, DMD, MScD\**

*Tiziano Testori, MD, DDS†*

*Alan Meltzer, DDS, MScD‡*

*Craig Misch, DDS, MDS§*

*Stephan Porter, DDS, MSD, MS||*

*Robert del Castillo, DMD\*\**


*Ronnie J. Goené, DDS††*

## Abstract:

For years, dental implants have been loaded immediately upon implant placement with varying degrees of success. As clinicians' understanding of the biological and mechanical factors involved in **immediate occlusal loading (IOL)** has evolved, the success of these procedures has increased—particularly as a treatment option for the restoration of the edentulous mandible or the mandible that will be rendered edentulous during treatment. Due to increasing interest in this treatment alternative, the authors have provided a clear definition of the terminology associated with IOL and have demonstrated the DIEM™ Guidelines used to increase the success and predictability of such treatment. This presentation also introduces new implant components that simplify the clinical application of the immediate loading concept, enhancing its benefits and acceptance among dental patients and practices alike.

## Key Words:

implant, immediate, occlusal, loading,  
mandible, edentulous



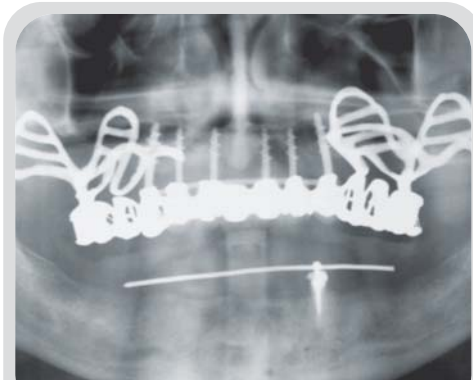


Figure 1 For years, implants have been immediately loaded as evident in this early example of the approach.

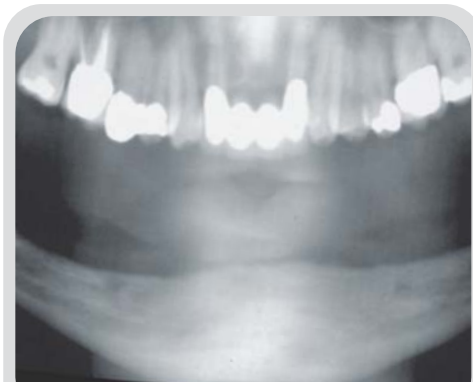

Figure 2 Case 1. Panoramic radiograph of patient's edentulous mandible prior to implant placement.

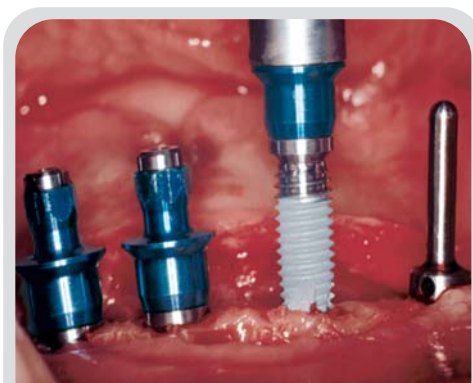


Figure 3 Five OSSEOTITE® implants were placed supra-crestally (without countersinking) in the patient's mandible.

The concept of immediately loading dental implants is not novel but extends back to the 1960s, when implant dentistry was still in its relative infancy. While implants of that period were often placed and immediately loaded (Figure 1), they did not always achieve the success rates that are observed and accepted today. Brånemark et al subsequently defined a surgical and restorative protocol that significantly increased the predictability of implant-supported prostheses.<sup>1</sup> As a result of this protocol, implant dentistry has gained in popularity and success as a means of treating edentulous patients.

While Brånemark listed several requirements for achieving implant success (including no radiographs until second-stage surgery, submerged placement, etc.), one of the principal determinants of success was the unloaded healing period postsurgery. According to the original Brånemark protocol,<sup>1</sup> dental implants, regardless of their design or system, required an undisturbed healing period of three months in the mandible and six months in the maxilla. While these periods purportedly allowed time for osseointegration of the implants within the respective arch, Brånemark's recommendations for healing were based on empirical data that were never scientifically proven and never experimentally ascertained. Brånemark granted that his results did not permit statistical evaluation of the separate parameters he believed contributed to the group's success.<sup>1</sup> As implantology has experienced numerous advances in implant designs as well as the surgical and restorative techniques, many clinicians have questioned whether or not the non-loaded healing period is still a valid prerequisite for success.<sup>2</sup> Complicating the issue, however, is that different definitions have been used to describe immediate loading, and it can be difficult for one to arrive at a clear understanding of the involved materials and clinical requisites.

This presentation defines the concepts involved in the immediate loading of dental implants. It also highlights the clinical requisites and components that improve the predictability and ease of use of the DIEM™ Guidelines. Additionally, it presents the authors' consensus regarding the surgical and restorative methods that maintain clinicians' expectations with this implant technique.



## Definitions of Immediate Loading

The numerous investigators who have explored immediate loading have done so with different definitions and evaluation criteria,<sup>2-12</sup> which has understandably contributed to the confusion that often surrounds the concept. It has been described as long as a 20-day period,<sup>13</sup> a 30-day period,<sup>14</sup> and is sometimes implied even when the implant restoration is not under full occlusal load.<sup>15</sup> At this time, the authors define the related terms accordingly:

■ **Immediate Occlusal Loading (IOL)**—An implant is placed with adequate primary stability; its corresponding restoration has full centric occlusion in maximum intercuspation and must be placed within 48 hours postsurgery (Figures 2 through 7). This process is based on the design of the restoration to prevent micromotion of the implant.

■ **Immediate Non-occlusal Loading**—An implant is placed with adequate primary stability but is not in functional occlusion. These implant restorations are essentially used for aesthetic purposes, frequently in single-tooth or short-span applications.<sup>16</sup> Immediate non-occlusal loading is often performed to provide the patient with aesthetic or psychological benefit during implant therapy, particularly when a provisional removable prosthesis is undesirable during the healing period.

■ **Early Loading**—An implant is placed with adequate primary stability and is placed under full occlusal load and prosthetic function within two months. A fundamental goal of early loading is improving bone formation in order to support occlusal loading at two months. Early loading, in contrast to immediate occlusal loading, is based on the interaction of the implant surface with the host bone for achieving biologic implant stability.

## Implant Stability

A fundamental requisite for IOL is adequate primary implant stability.<sup>17-20</sup> While stability was traditionally achieved through a period of undisturbed healing (ie, osseointegration), primary stability is now achieved via a mechanical

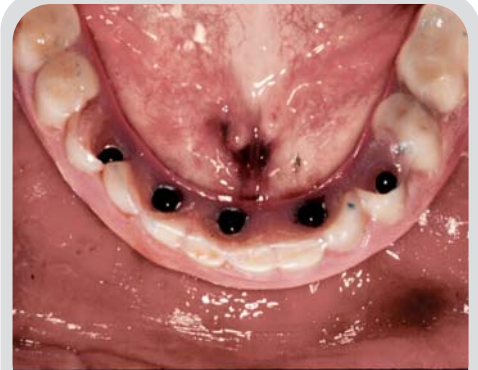

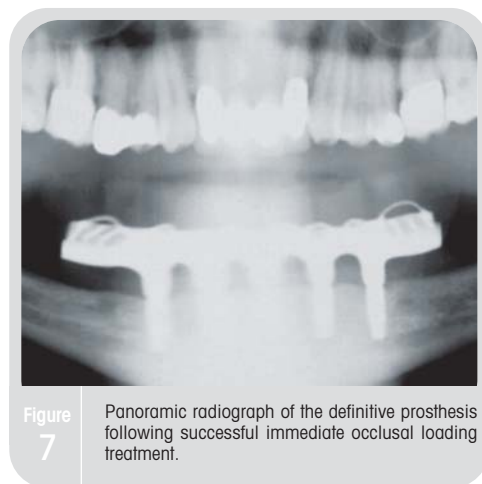
Figure 4 Occlusal view shows a fixed prosthesis delivered to the patient following immediate implant placement and loading.

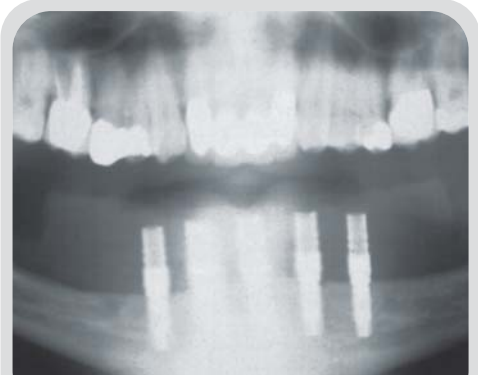

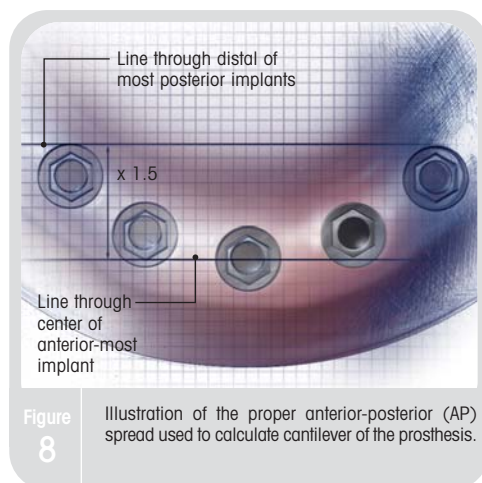
Figure 5 Postoperative radiograph of the mandibular implants on the day of placement and loading.

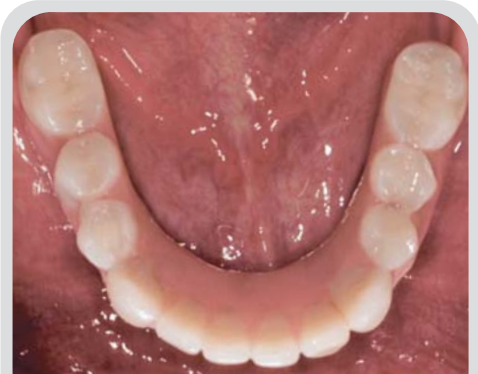

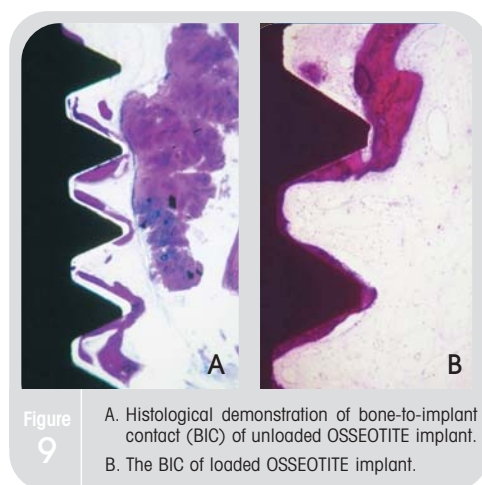
Figure 6 Occlusal view of the definitive implant prosthesis that restored the patient to function.



**Figure 7** Panoramic radiograph of the definitive prosthesis following successful immediate occlusal loading treatment.



**Figure 8** Illustration of the proper anterior-posterior (AP) spread used to calculate cantilever of the prosthesis.



**Figure 9** A. Histological demonstration of bone-to-implant contact (BIC) of unloaded OSSEOTITE implant. B. The BIC of loaded OSSEOTITE implant.

phenomenon of screw stability and splinting. Primary implant stability can be measured via insertion torque values or resonance frequency analysis (RFA). The connection of implants to preexisting rigid members such as stable teeth or integrated implants may also address the goal of preventing lateral movement (ie, micromotion) of the implant during healing as well.

Each implant system tolerates micromotion differently. For implants with roughened surfaces, tolerance is in the range of  $50\mu\text{m}$  to  $150\mu\text{m}$ <sup>17,18,20</sup>; machined surfaces can withstand approximately  $100\mu\text{m}$  of micromovement.<sup>19</sup> Regardless of the type of implant selected, all restorative procedures should be completed within two days of implant placement according to the specific needs of the patient and after which time bone healing and implant stability may be disrupted by such intervention.<sup>21</sup>

### Indications for the Fully Edentulous Mandible

Each patient must be evaluated preoperatively to ensure that he or she satisfies clinical criteria for an IOL protocol, of which requisites include the following:

- Adequate bone quality (Types I, II, or III)
- Sufficient bone height (ie, approximately 12mm) for a minimum length 10mm implant
- Sufficient bone width (ie, approximately 6mm)
- Ability to achieve an adequate anterior-posterior (AP) spread between the implants. A poor AP spread decreases the mechanical advantage gained by splinting and the ability to cantilever the restoration (Figure 8).<sup>22</sup>

### Contraindications for the Fully Edentulous Mandible

An immediate loading DIEM™ protocol is generally contraindicated in patients with the following conditions:

- Poor systemic health
- Severe parafunctional habits
- Bone of poor quality (eg, Type IV bone)
- Bone height less than 12mm
- Bone width less than 6mm
- Inability to achieve an adequate AP spread.

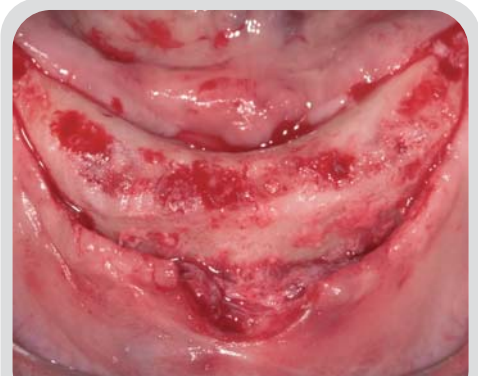## Advantages and Disadvantages of Immediate Occlusal Loading

The immediate occlusal loading of implants continues to be the subject of clinical investigations due in part to the advantages that it presents to dental professionals. Among these benefits are the following:

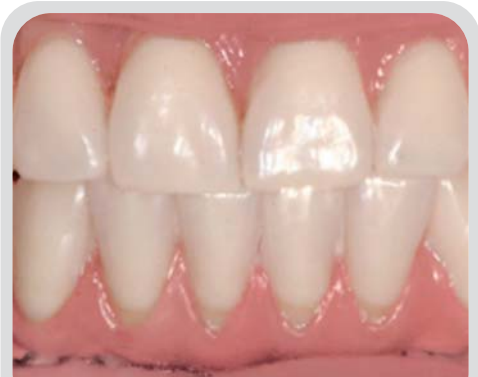- Eliminates the need for and maintenance of a removable provisional prosthesis
- Provides emotional benefit for a patient scheduled to be rendered edentulous
- Improves bone healing<sup>23,24</sup>
- Facilitates soft tissue shaping
- Eliminates premature implant exposure often associated with wearing of a removable denture during healing period.

Immediate loading can be advantageous to dental patients as well. In publications regarding conventional implant treatment,<sup>25</sup> patients have cited complaints that include 1) loose-fitting dentures, 2) denture sore spots, 3) difficulty chewing, 4) difficult postoperative periods, and 5) the number of visits required to maintain the prosthesis. Immediate implant loading provides improved function, aesthetics, and psychological benefits to such patients, and it can have a favorable cost/benefit with regard to timing of treatment.

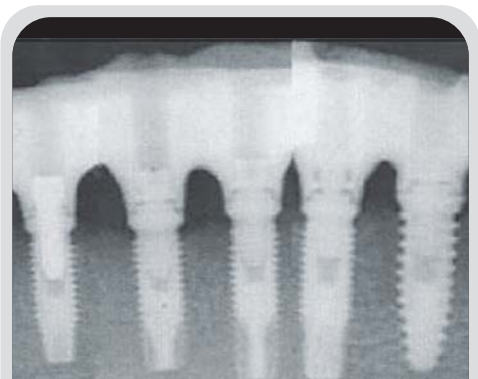
This approach cannot, however, be applied to every implant patient. In comparison to conventional implant therapy, the IOL procedure requires more chair time at the time of implant placement for both the patient and the restorative practitioner. Immediate loading also requires effective communication and coordination among the surgical and restorative teams, as there is a degree of flexibility involved in the delivery of the prosthesis. For example, the surgical and restorative procedures can be completed in a single appointment for straightforward cases. For other cases, the prosthesis may be more appropriately delivered one to two days following implant placement, and the clinician must understand the difference between these options.<sup>21</sup> Careful patient screening and selection are required when an IOL procedure is a treatment consideration. As mentioned previously,



**Figure 10** Case 2. Occlusal view of full-thickness flaps in fully edentulous mandible that will be treated following the DIEM Guidelines.



**Figure 11** Facial view of completed implant prosthesis.



**Figure 12** Postoperative radiograph of IOL treatment demonstrates implant integration and good bone levels.

immediate loading requires adequate primary stability as well as bone quality.

## Investigations and Experiences

Numerous investigators have studied immediate implant loading in order to more fully understand the variables that influence its success, yielding more than 50 publications on the topic in 2003 alone. Based on a recent review of 153 publications on immediate loading, Del Fabbro et al have confirmed the effectiveness and safety of its application in the fully edentulous mandible.<sup>26</sup>

Other investigations have sought to confirm the efficacy of immediate loading by measuring the extent of osteogenesis and bone remodeling around OSSEOTITE® implants (3i, Implant Innovations, Inc., Palm Beach Gardens, FL) placed using this protocol.<sup>23</sup> Clinical and histological examination of two implants retrieved from the 12 implants originally placed in the patient using the IOL procedure revealed high levels of bone-to-implant contact (BIC) that ranged from 78% to 85%. These findings for bone apposition have been achieved in similar studies in which both loaded and unloaded implants have been placed, allowed to integrate, and were later (after two months) retrieved.<sup>27</sup> Upon examination, all OSSEOTITE implants were clinically stable, and histological examination revealed BIC of 38.9% and 64.2% for unloaded and loaded implants, respectively (Figure 9). Most interestingly, the authors discovered that if an IOL procedure was used and the implants were stabilized throughout the follow-up period, bone apposition would increase around the implant. These results were consistent with those of additional long-term studies on more patients with greater numbers of implants (Table 1).<sup>28</sup> Each of these IOL procedures was successful to a significant extent based on the clinicians' ability to limit micromotion with the provisional prosthesis and to achieve cross-arch stabilization (Figures 10 through 12).

These findings have confirmed similar results achieved in animal models.<sup>24,29</sup> In the histological study performed by Piatelli et al, BIC in immediately occlusally loaded test subjects (67.3% in the maxilla and 73.2% in the mandible)

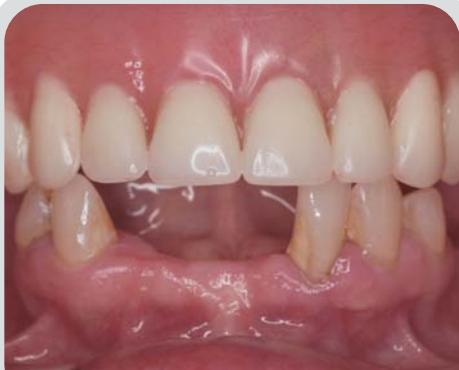

Figure 13 Case 3. Preoperative facial view of patient, whose mandible will be rendered fully edentulous during the DIEM procedure.

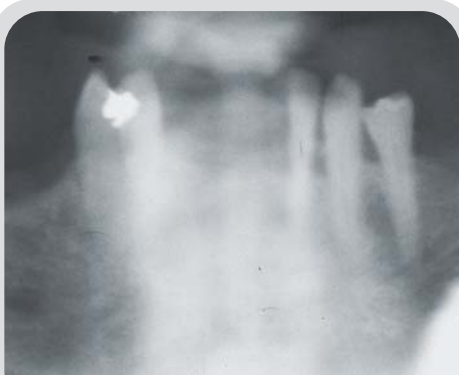

Figure 14 Panoramic radiograph taken prior to tooth extraction and initiation of the IOL procedure.

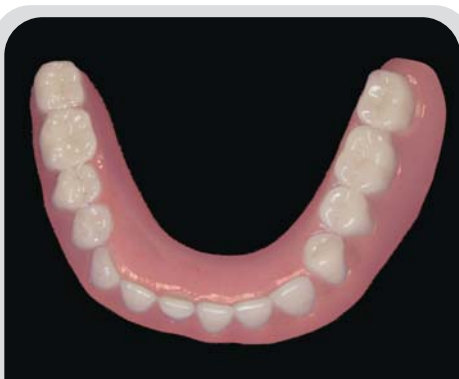

Figure 15 View of immediate provisional denture that will be used following the DIEM Guidelines.



**Table 1: Life Table Analysis of 325 Immediately Loaded Implants**

Interval time (months)	Failed implants	Interval survival rates (%)	Cumulative survival rate (%)
0-4	2	99.38	99.38
6-12	0	100	99.38
12-18	0	100	99.38
18-24	0	100	99.38
24-36	0	100	99.38
36-48	0	100	99.38
48-60	0	100	99.38
>60	0	100	99.38

Testori T et al 2003

was greater than in non-immediately loaded control subjects (54.5% in the maxilla and 55.8% in the mandible). In the histological and histomorphometric evaluation,<sup>29</sup> immediately loaded and splinted implants in the mandible demonstrated a hard tissue response similar to that of delayed loaded implants. These investigators also concluded that BIC was the same and that IOL appeared to increase the ossification of the alveolar bone around the implants.

### Extrapolating From Clinical Data On Successful Implant Placement

Long-term data evidencing the success rates of the OSSEOTITE implant future supports the IOL of the edentulous mandible.<sup>23,28,30-32</sup> Based on the proven success of implant survival, prosthesis survival and aesthetics, all of which are supported by controlled human multi-center studies, the authors have adopted DIEM™ Guidelines (from the Latin word for 'day') and specifically designed IOL™ Components for the predictable treatment of the fully edentulous mandible or the mandible that will be rendered fully edentulous during treatment.

The armamentarium supporting DIEM™ is simple to use, inexpensive, and provides the practitioner with the flexibility

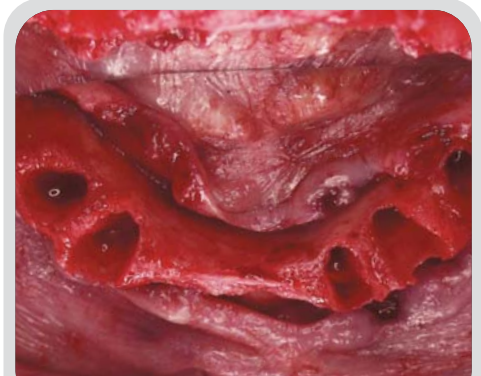


Figure 16

The patient's mandibular ridge following tooth extraction and prior to implant placement.

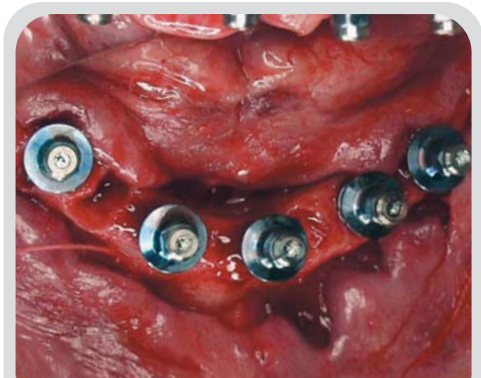


Figure 17

Five OSSEOTITE® implants (3i, Palm Beach Gardens, FL) are placed in the mandible according to the surgical guide.

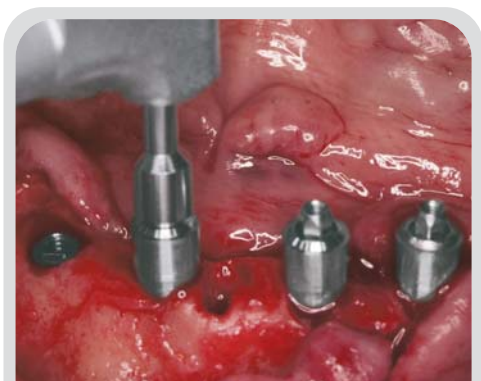

Figure 18

IOL™ Abutments are selected for each implant and connected accordingly.

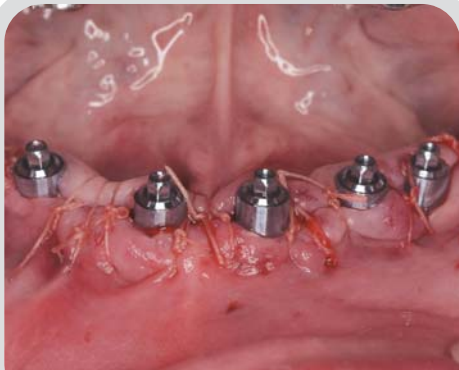

Figure 19 The flaps are sutured around the IOL Abutments. Note that abutments are supragingival.

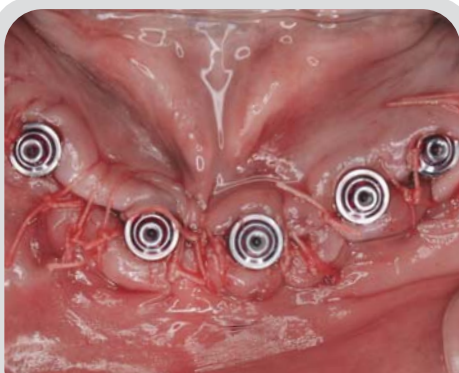


Figure 20 Bioabsorbable sutures may prove beneficial when used following the DIEM Guidelines.

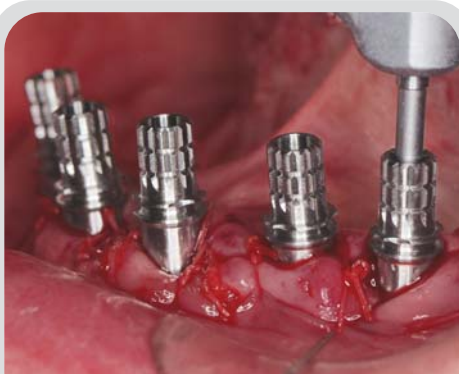

Figure 21 IOL Temporary Cylinders are selected and connected to the abutments.

to address a wide variety of clinical conditions during treatment. In this last regard, DIEM can be used with either internally connected or externally hexed parallel wall or tapered implants as well as definitive prostheses of varying styles (eg, metal-ceramic bridges or fixed-detachable bridges). Using this technique and the associated IOL™ Components, dental professionals can now overcome many of the limitations (eg, duration of anesthesia, fatigue, patient bleeding, lack of distal prosthesis support) that had traditionally complicated immediate loading procedures. Ultimately, the DIEM Guidelines allow the practitioner to deliver predictable results, ensuring that patient care and the long-term success of the definitive prosthesis remain the focus of the restorative procedure.

### Demonstration of the DIEM Guidelines and IOL Components

Treatment planning according to the DIEM Guidelines generally follows the accepted surgical protocol for any IOL procedure. Thus, the appropriate provisional prosthesis and/or surgical guides must be prepared prior to implant placement (Figures 13 through 15). When preparing the surgical guide, the guide holes should be positioned so that the implant locations provide an adequate AP spread. Alternately, holes can be drilled in the patient's existing denture in the desired implant positions. Once the stability of the denture is verified intraorally, the opposing occlusion must be evaluated. The use of the DIEM Guidelines depends on the patient's ability to achieve maximum intercuspation in order to facilitate the construction of the provisional prosthesis. A bite registration is necessary to minimize occlusal adjustments on the provisional prosthesis.

#### ■ Implant Placement

The ridge of the patient's mandible is prepared with the required releasing incisions and flap elevation (Figure 16) (Table 2). The denture or surgical guide is then placed to facilitate visualization and location of the five implants that will support the provisional prosthesis. Any OSSEOTITE® implant can be used with the DIEM procedure and

the IOL Components. Any adjustments in location or protocol required to ensure a proper AP spread and primary stabilization should also be performed.

**Table 2:**

**Ridge Preparation Guidelines**

- Reduce knife-edge crest so that ridge is at least 6mm wide
- Reduce depth of sockets so that if the socket is used as an implant site:
  - The implant placement will obliterate the socket or
  - The implant placement will leave a space of 1.5mm or less between the implant and the socket wall and
  - Three quarters of the implant surface is in direct contact with host bone and
  - The head of the implant is contained within the socket.

The classical drilling sequence should then be performed for the operator’s implant of choice. Site preparation is initiated with a 2-mm twist drill. Once this initial drill is withdrawn from the site, a direction indicator pin is placed to allow verification of the denture or surgical guide’s position. The osteotomy then continues to the proper depth with the corresponding drills. This sequence should first be performed for the most central implant, then for the two most posterior implants, and then the two remaining sites (Figure 17). The implants were placed according to the manufacturer’s protocol, and forward torque is then applied to at least 20 Ncm to confirm primary stability. If the implants are stable in the mandible, the DIEM procedure can continue; if the implants exhibit some degree of motion, then the clinician should opt instead for a two-stage surgical technique with a non-loaded protocol.

■ **Placement of IOL Abutments**

The IOL Abutments are selected and placed with the abutment driver (Figure 18). Developed for 4.1mm platform

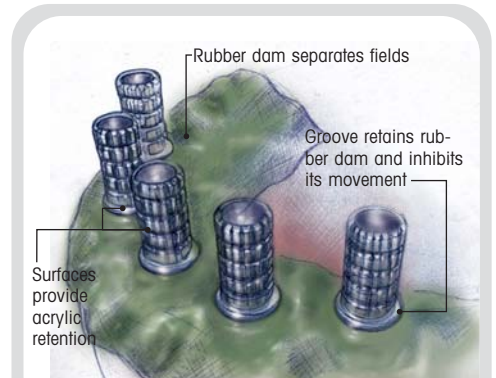


Figure 22

Illustration demonstrates the placement of the rubber dam that divides the surgical and prosthetic fields.

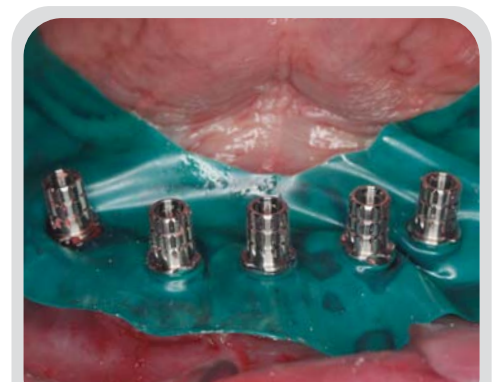


Figure 23

Holes are created in the rubber dam, which is positioned in the retention groove on the temporary cylinders.

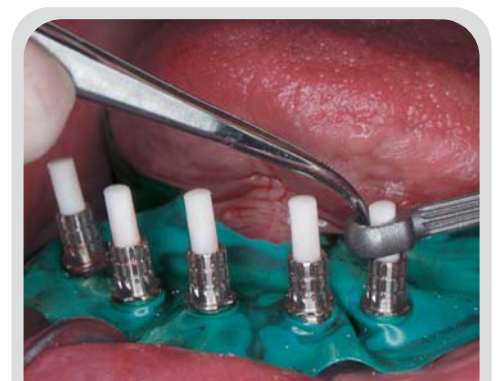
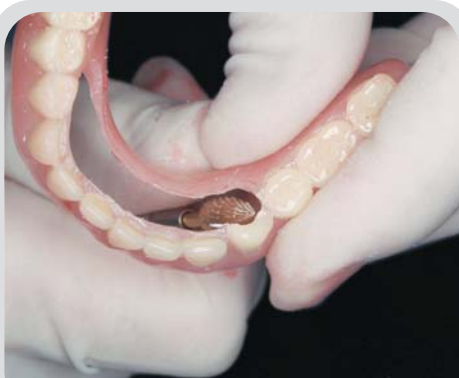
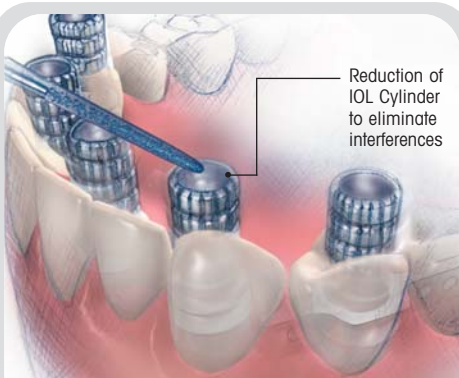
Figure 24

The Distal Extension Support is placed over the IOL Temporary Cylinder and affixed with acrylic resin.

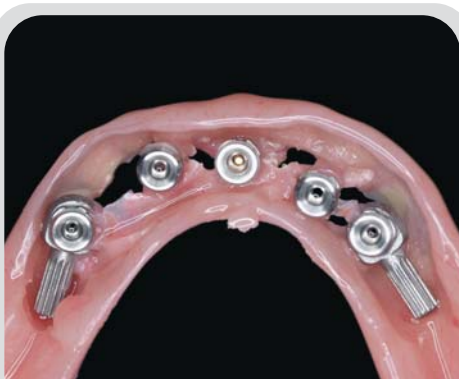




**Figure 25** The prosthesis is adjusted chairside, hollowed out to permit positioning over the IOL Temporary Cylinders.



**Figure 26** Illustration depicts the reduction of the IOL Temporary Cylinders, which may be required for occlusal clearance.



**Figure 27** Acrylic resin is applied to the intaglio surface of the denture to fill all voids.

3i OSSEOTITE implants, these abutments range in height from 2mm to 7mm. The unique design of the IOL Abutment allows for implant divergence of up to 40 degrees off-axis while still allowing a positive seat of the prosthesis to the abutment seating surface. Clinicians can thus adopt the appropriate IOL Abutment for the requirements of each patient's mandible. The height of the abutment collar should be approximately 1mm to 2mm supragingivally and as parallel to the ridge as possible. Abutment screws are tightened to 20 Ncm of torque, and the flaps closed and sutured (Figures 19 and 20). The authors recommend the utilization of a two-layer horizontal mattress closure that uses bioabsorbable sutures to eliminate the need to remove the prosthesis to facilitate suture removal during the eight-week period of osseointegration.

#### ■ IOL Temporary Cylinder Placement

In the restorative phase of treatment, the prosthetic field is isolated from the surgical field with a rubber dam. A notable innovation of the IOL Temporary Cylinder is the groove that maintains the coronal position of the dam. This enables the restorative aspects of the case to be conducted without disturbing the underlying, sutured soft tissue and isolates the surgical site from the restorative procedure. The temporary cylinders are connected to the implant abutments and secured with retaining screws (Figures 21 through 23). If Distal Extension Supports are desired to support distal cantilevers in the transitional IOL prosthesis, they should be added at this time over the two most posterior IOL Abutments and secured with acrylic resin (Figure 24).

#### ■ Adjustment and Integration of the Provisional Denture

The position of the denture is verified over the IOL Temporary Cylinders and is adjusted as necessary to ensure that it has no interferences with the abutments and cylinders during seating (Figure 25). The occlusion is checked and, if interferences are present, the height of the corresponding cylinder should be reduced but not excessively—it should only clear the opposing dentition during occlusion at this time (Figure 26).

Filler material (eg, wax, cotton) should be placed in the access hole of each cylinder to ensure that no acrylic



resin will enter this opening and interfere with access to the retaining screw. The denture is positioned over the temporary cylinders using occlusion with the opposing dentition as a guide. Next, the denture is secured to the anterior-most temporary cylinder with small drops of acrylic resin using a bead-brush technique (Table 3), and the patient occludes until the resin sets. The patient's vertical dimension of occlusion (VDO) is verified at this time. This process is then repeated on the remaining cylinders until the temporary denture has been secured to all of them.

**Table 3:**

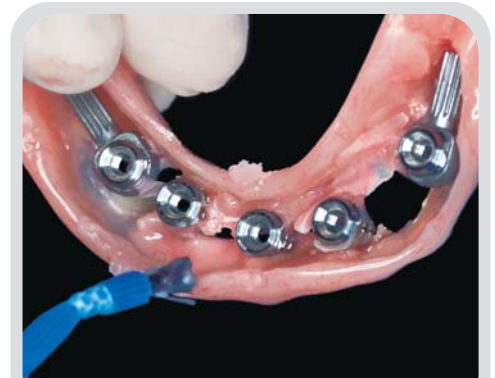**Guidelines for Attaching the Temporary Denture to the IOL Temporary Cylinders**

- Position denture—tissue bearing
- Have the IOL™ Temporary Cylinder protrude through the hole(s) in the denture without interferences
- Select the most accessible denture window (or hole) and cylinder, and add a few drops of acrylic around the cylinder using the bead-brush technique
- Prior to the acrylic setting, have the patient occlude into the previously made bite registration and hold the closed position until the acrylic sets
- With the denture locked in position, repeat the process for the remaining cylinders, verifying the occlusion after each cylinder is attached

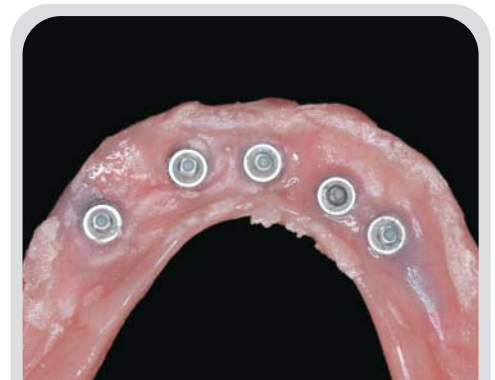The retaining screws are then unscrewed to allow the prosthesis to be removed from the patient's mouth. Flanges are removed and voids in the prosthesis are filled with acrylic, and the temporary cylinders are reduced or made flush. To avoid acrylic flowing into the temporary cylinders, implant analogs can be attached to each cylinder prior to filling of voids.

**■ Completion of the Denture**

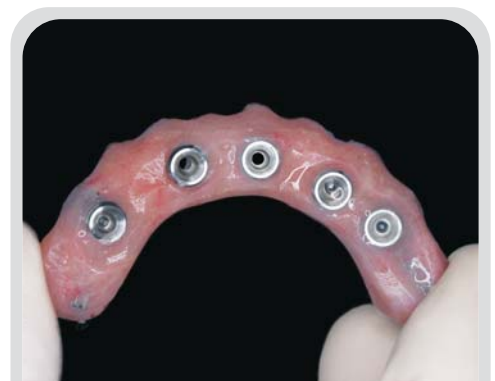Using acrylic resin to fill any remaining voids (Figures 27 through 29), the provisional denture is converted into a fixed provisional restoration and seated on the abutments.



**Figure 28** Additional acrylic resin is added to the prosthesis to fill the voids.



**Figure 29** All voids have been filled, and the immediate provisional prosthesis is ready for reduction, finishing, and polishing.



**Figure 30** Prosthesis following finishing and polishing. Note removal of flanges and support of distal regions by Distal Extension Supports.

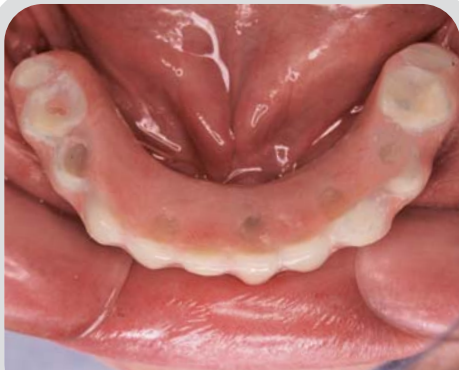

Figure 31 Occlusal view of the provisional prosthesis in situ with access openings filled.

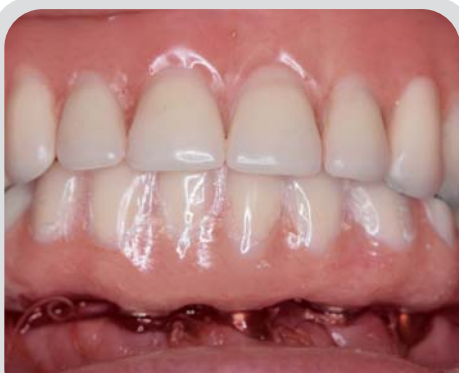

Figure 32 Facial view of the prosthesis delivered according to the DIEM™ Guidelines and with IOL Components.

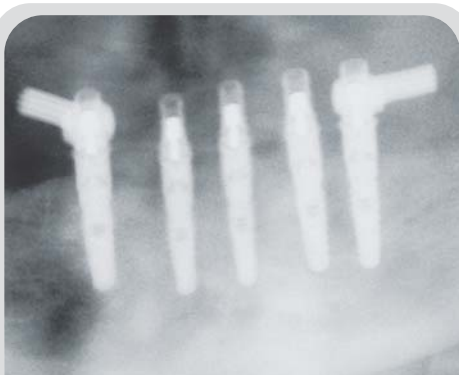

Figure 33 Postoperative panoramic radiograph demonstrates seating of the transitional implant restoration.

To facilitate cleansing and function, excess resin and all flanges should be removed (Figure 30), and the denture should be polished prior to intraoral placement (Figure 31). Occlusion is then evaluated, and any undesirable contact areas are eliminated. The denture is then returned to the patient's mouth, placed on the abutments, and secured with Gold-Tite™ retaining screws at 10 Ncm of torque (Figures 31 through 33).

The patient should be placed on a soft diet for a two-week period and return for evaluation. At approximately eight weeks following the initial implant placement, the immediate fixed provisional restoration can be removed for the first time to permit the impression making required for the fabrication of the definitive prosthesis.

## Conclusion

Clinicians' search for means of restoring their patients efficiently and effectively is not novel, nor is the concept of immediate implant loading. Reports on IOL procedures continue to proliferate in the literature and, while advocating different protocols, they demonstrate the overall successes on which the DIEM Guidelines are based. The DIEM technique highlighted herein is predicated on the combination of biological and mechanical guidelines, the adaptation of existing prosthetic concepts, and new data. When supplemented by innovative implant components, these factors provide dental professionals with a set of simple guidelines to produce successful outcomes in a variety of offices with dentists working independently or as part of a team. This approach allows the clinician to customize the technique to the anatomical differences among patients, thus avoiding the need to modify patient treatment to fit a given restorative solution. Future considerations for IOL and other dedicated components and the DIEM Guidelines include their application in the maxilla and partially edentulous patients. While preliminary data collected for these sites are promising, further research and evaluation is ongoing to confirm their long-term success and potential for use in daily restorative practice.

## References

1. Brånemark P-I, Hansson BO, Adell R, et al. Osseointegrated implants in the treatment of the edentulous jaw. Experience from a 10-year period. *Scand J Plast Reconstr Surg* 1977;16:1-132.
2. Schnitman PA, Wöhrle PS, Rubenstein JE. Immediate fixed interim prostheses supported by two-stage threaded implants: Methodology and results. *J Oral Implant* 1990;16(2):96-105.
3. Schnitman PA, Wöhrle PS, Rubenstein JE, et al. Ten-year results for Brånemark implants immediately loaded with fixed prostheses at implant placement. *Int J Oral Maxillofac Implants* 1997;12(4):495-503.
4. Salama H, Rose LF, Salama M, Betts NJ. Immediate loading of bilaterally splinted titanium root-form implants in fixed prosthodontics—A technique reexamined: Two case reports. *Int J Periodontics Rest Dent* 1995;15(4):344-361.
5. Chaushu G, Chaushu S, Tzohar A, Davan D. Immediate loading of single-tooth implants: Immediate versus non-immediate implantation: A clinical report. *Int J Oral Maxillofac Implants* 2001;16(2):267-272.
6. Colomina LE. Immediate loading of implant-fixed mandibular prostheses: A prospective 18-month follow-up clinical study—Preliminary report. *Implant Dent* 2001;10(1):23-29.
7. Tarnow DP, Emtiaz S, Classi A. Immediate loading of threaded implants at stage 1 surgery in edentulous arches: Ten consecutive case reports with 1- to 5-year data. *Int J Oral Maxillofac Implants* 1997;12(3):319-324.
8. Balshi TJ, Wolfinger GJ. Immediate loading of Brånemark implants in edentulous mandibles: A preliminary report. *Implant Dent* 1997;6(2):83-88.
9. Testori T, Szmuckler-Moncler S, Francetti L, et al. Immediate loading of Osseotite implants: A case report and histologic analysis after 4 months of occlusal loading. *Int J Periodont Rest Dent* 2001;21:451-459.
10. Ericsson I, Nilson H, Lindh T, et al. Immediate functional loading of Brånemark single-tooth implants. An 18 months' clinical pilot follow-up study. *Clin Oral Implants Res* 2000;11(1):26-33.
11. Ganeles J, Rosenberg MM, Holt RL, Reichman LH. Immediate loading of implants with fixed restorations in the completely edentulous mandible: Report of 27 patients from a private practice. *Int J Oral Maxillofac Implants* 2001;16(3):418-426.
12. Aparicio C, Ranger B, Sennerby L. Immediate/early loading of dental implants: A report from the Sociedad Espanola de Implantos World Congress consensus meeting in Barcelona, Spain, 2002. *Clin Implant Dent Relat Res* 2003;5(1):57-60.
13. Randow K, Ericsson I, Nilner K, et al. Immediate functional loading of Brånemark dental implants. An 18-month clinical follow-up study. *Clin Oral Impl Res* 1999;10(1):8-15.
14. Cooper LF, Rahman A, Moriarty J, et al. Immediate mandibular rehabilitation with endosseous implants: Simultaneous extraction, implant placement, and loading. *Int J Oral Maxillofac Implants* 2002;17:517-525.
15. Malo P, Ranger B, Dvarstater L. Immediate function of Brånemark implants in the esthetic zone: A retrospective clinical study with 6 months to 4 years of follow up. *Clin Impl Relat Res* 2000;2(3):138-146.
16. Wöhrle PS. Single-tooth replacement in the aesthetic zone with immediate provisionalization: Fourteen consecutive cases. *Pract Periodont Aesthet Dent* 1998;10(9):1107-1114.
17. Szmuckler-Moncler S, Piatelli A, Favero GA, Dubruille JH. Considerations preliminary to the application of early and immediate loading protocols in dental implantology. *Clin Oral Impl Res* 2000;11(1):12-25.
18. Soballe K. Hydroxyapatite ceramic coating for bone implant fixation. Mechanical and histological studies in dogs. *Act Orthop Scan Suppl* 1993;255:1-58.
19. Vaillancourt H, Pilliar RM, McCammond D. Finite element analysis of crestal bone loss around porous-coated dental implants. *J Appl Biomater* 1995;6(4):267-282.
20. Brunski JB. Biomechanical factors affecting the bone-dental implant surface. *Clin Mater* 1992;10(3):153-201.
21. Testori T, Meltzer A, Del Fabbro M, et al. Immediate occlusal loading of Osseotite implants in the lower edentulous jaw. *Clin Oral Impl Res* 2004;15(Accepted for publication).
22. English CE. The critical A-P spread. *Implant Society* 1990;1(1):2-3.
23. Testori T, Woolfe S, Porter SS, Wiseman L. A prospective multicenter study of the Osseotite implant: A four-year interim report. *Int J Oral Maxillofac Implants* 2001;16:193-200.
24. Piatelli A, Corigliano M, Scarano A, et al. Immediate loading of titanium plasma-sprayed implants: An histologic analysis in monkeys. *J Periodontol* 1998;69:321-327.
25. Jivraj SA, Chee WW. An interdisciplinary approach to treatment planning in the esthetic zone. *J Calif Dent Assoc* 2003;31(7):544-549.
26. Del Fabbro M, Testori T, Francetti L, et al. A meta-analysis on survival rate of endosseous implants. *Int J Oral Maxillofac Implants* 2004;19(Accepted for publication).
27. Testori T, Szmuckler-Moncler S, Francetti L, et al. Healing of Osseotite implants under submerged and immediate loading conditions in a single patient: A case report and interface analysis after 2 months. *Int J Periodont Rest Dent* 2002;22:345-353.
28. Testori T, Del Fabbro M, Szmuckler-Moncler S, et al. Immediate occlusal loading of Osseotite implants in the completely edentulous mandible. *Int J Oral Maxillofac Implants* 2003;18:544-551.
29. Romanos GE, Toh CG, Siar CH, Swaminathan D. Histologic and histomorphometric evaluation of peri-implant bone subjected to immediate loading: An experimental study with macaca fascicularis. *Int J Oral Maxillofac Implants* 2002;17:44-51.
30. Grunder U, Gaberthuel T, Boitel N, et al. Evaluating the clinical performance of the Osseotite implant: Defining prosthetic predictability. *Compend Contin Educ Dent* 1999;20:628-640.
31. Lazzara RJ, Testori T, Trisi P, et al. A human histologic analysis of Osseotite and machined surfaces using implants with two opposing surfaces. *Int J Periodont Rest Dent* 1999;19:117-129.
32. Sullivan DY, Sherwood RL, Porter SS. Long-term performance of Osseotite implants: A six-year follow-up. *Compend Contin Educ Dent* 2001;22:326-334.

\* *Private practice, specializing in implant dentistry, West Palm Beach, FL; Clinical Assistant Professor, University of Southern California School of Dentistry, Los Angeles, CA.*

† *Assistant Clinical Professor and Head of the Section of Implant Dentistry and Oral Rehabilitation, Department of Odontology, Galaezzi Institute, University of Milan; private practice, Como, Italy.*

‡ *Diplomate, American Academy of Periodontology; Associate Clinical Professor, Department of Implant Dentistry, New York University College of Dentistry, New York, NY; private practice, specializing in periodontics and implant dentistry, Voorhees, NJ.*

§ *Private practice, Oral and Maxillofacial Surgery, Sarasota, FL; Clinical Associate Professor, Department of Implant Dentistry, New York University College of Dentistry, New York, NY.*

|| *Private practice, Surgical and Prosthetic Treatment with an emphasis on Implant Prosthetics, West Palm Beach, FL.*

\*\* *Private practice, specializing in periodontics and implant dentistry, Miami Lakes, FL; Adjunct Professor, Department of Periodontics, Tufts University School of Dental Medicine, Boston, MA.*

†† *Associate Professor, Department of Oromaxillofacial Surgery, ACTAVU Medical Center, Amsterdam, Netherlands.*