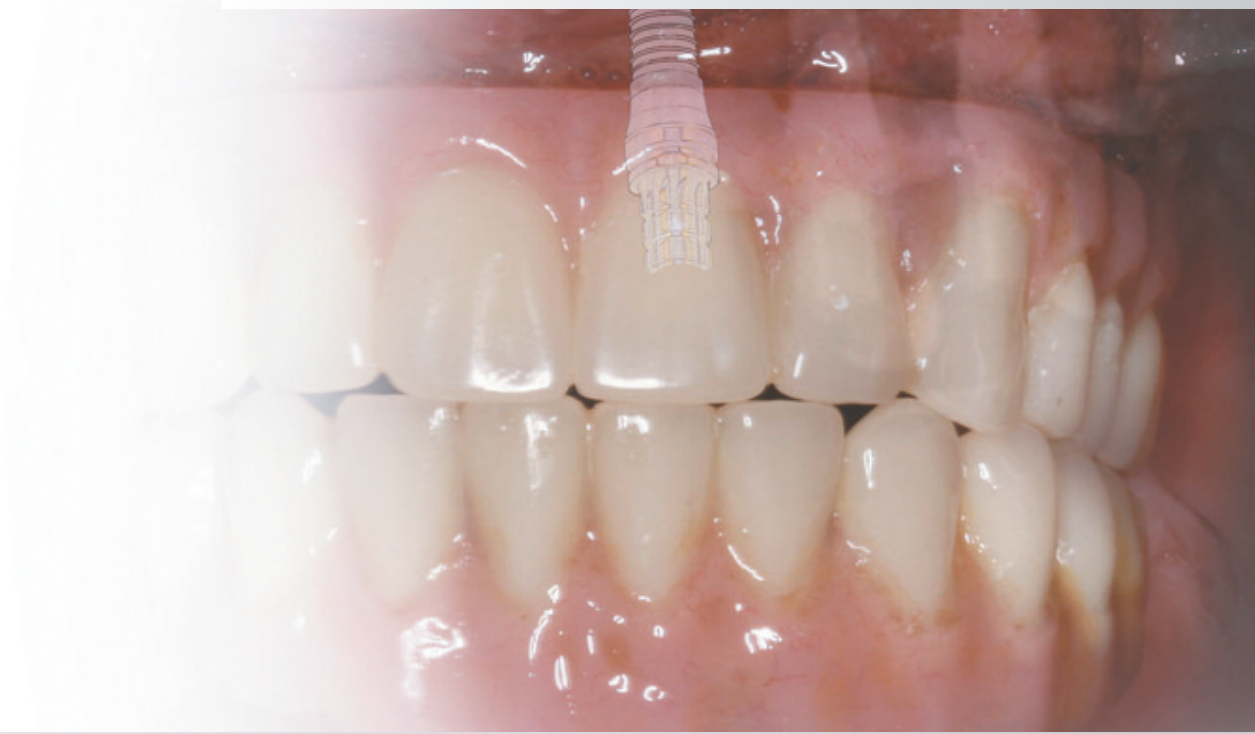



CLINICAL PERSPECTIVES

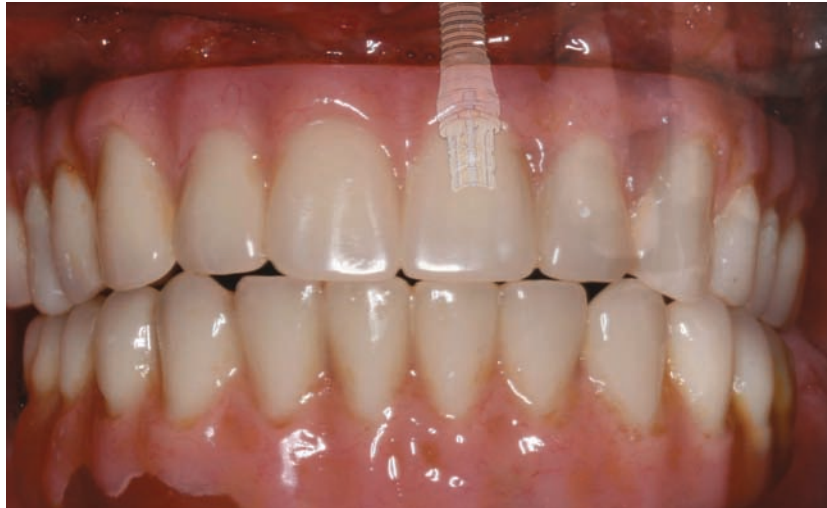Inside this issue:

Implant placement and immediate provisional restoration
of edentulous arches: A case presentation

CLINICAL PERSPECTIVES

Implant placement and immediate provisional restoration of edentulous arches: A case presentation

Brent R. Boyse, DDS* and Sheldon Sullivan, DDS*



Extraction, with immediate implant placement, restoration, and loading has become an attractive option for meeting some of the aesthetic and biomechanical challenges associated with using implants to replace single or multiple teeth, particularly in the aesthetic zone. Patients desiring improvement of their smiles with fixed restorations, along with aesthetic enhancements and improved function, represent a growing segment of the population.

Key Words: immediate provisionalization, Low Profile Abutments, screw-retained abutments, tapered implants

Introduction

This Clinical Perspectives demonstrates a patient who presented with a debilitated dentition. The treatment plan accepted by the patient included extractions, bilateral sinus lifts/grafting, immediate implant placement and immediate occlusal loading, in a staged approach to treatment. This complex treatment is a good example of the cooperation that is necessary among the dental implant team—surgeon, restorative dentist, and laboratory technician.

Clinical Case Presentation

The following clinical case presentation demonstrates the treatment of a 56 year old male patient who presented with advanced, generalized periodontitis. His chief complaint was “my teeth are falling out and I have pain in my teeth.” The patient desired treatment that would provide him with fixed implant supported restorations. He wished to avoid complete dentures.

At the clinical examination, 2+ mobility was noted for all teeth (Fig. 1). Radiographs demonstrated moderate to severe bone loss (Fig. 2). Additional clinical and radiographic examinations confirmed that the patient had inadequate bone volume to allow for placement of dental implants immediately

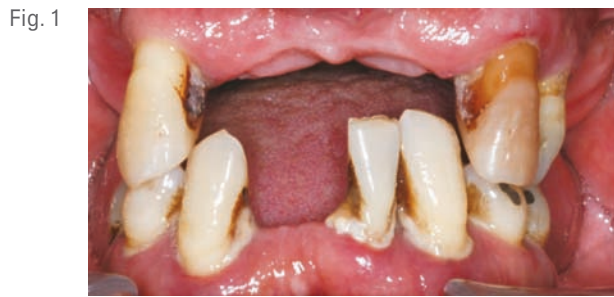

Fig. 1

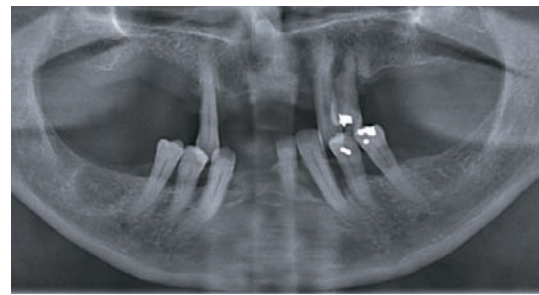


Fig. 2

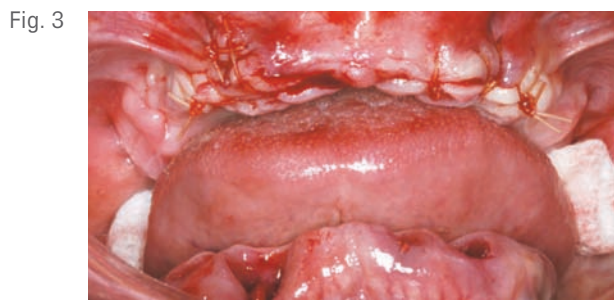

Fig. 3

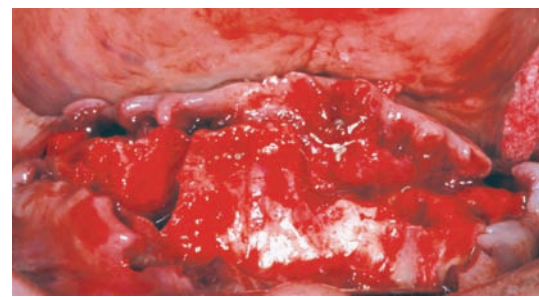


Fig. 4

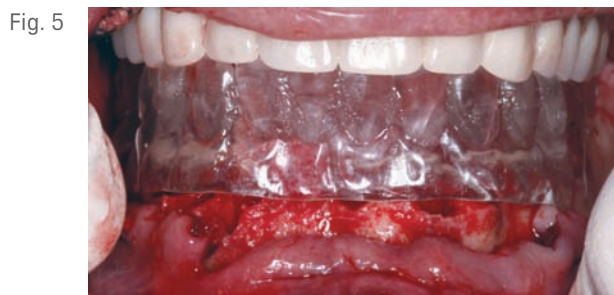

Fig. 5

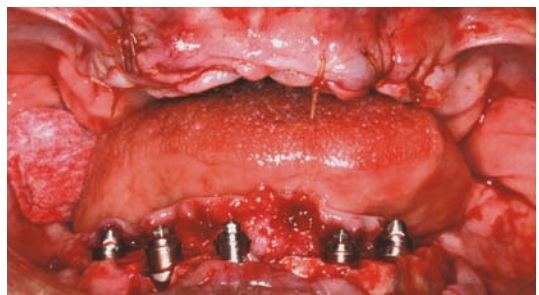

Fig. 6

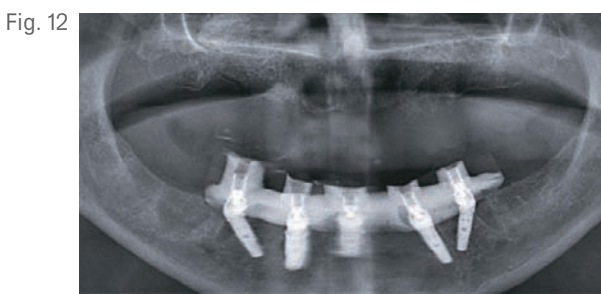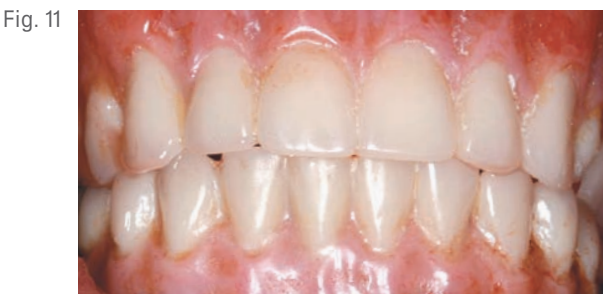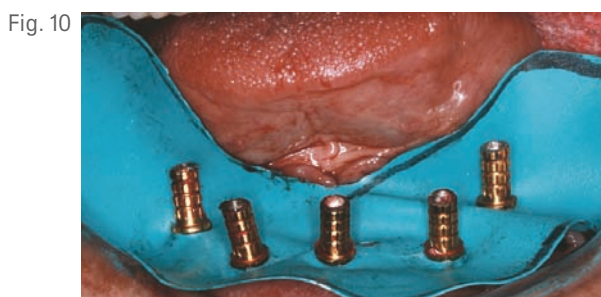
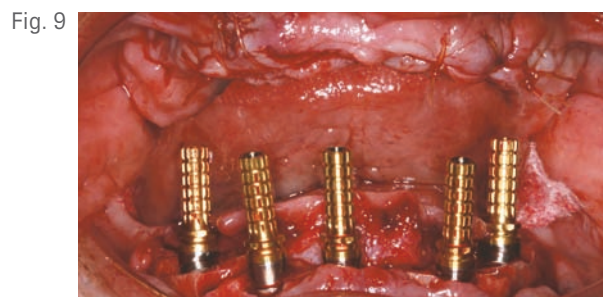
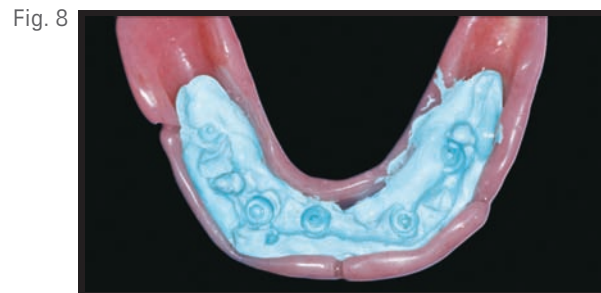

following extraction of the hopeless maxillary dentition, therefore, a staged approach to treatment was deemed appropriate. The mandibular arch presented with adequate bone volume, however there was minimal restorative volume for immediate implant placement with a fixed implant-supported provisional restoration.

Phase I Treatment

Phase I included extractions of the teeth in both arches, bilateral maxillary sinus lifts and an anterior tunnel graft; placement of mandibular implants (Figs. 3 and 4) and conversion of an immediate denture to a fixed, implant-retained prosthesis, following the DIEM® 2 Guidelines. The surgeon chose to extract the maxillary teeth and place the immediate maxillary denture first. Every effort was

made to maximize the interarch distance. However, the patient presented with relatively short alveolar processes and interarch space was limited.

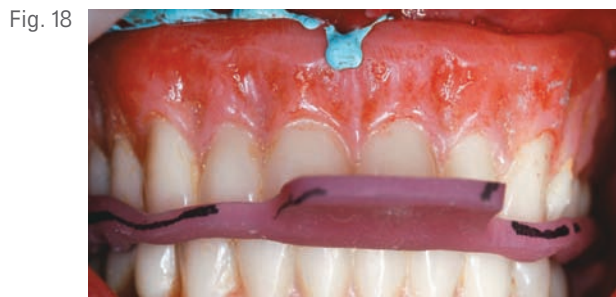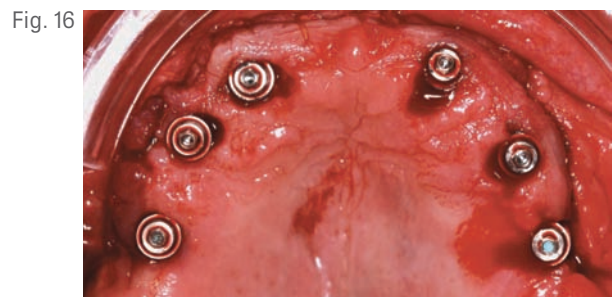
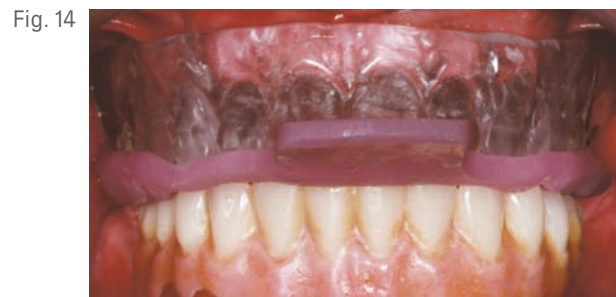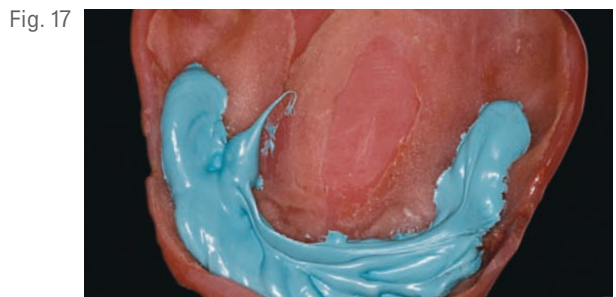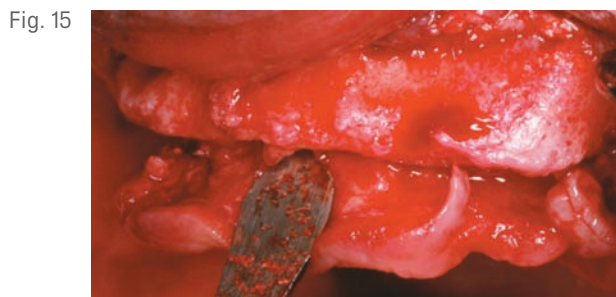
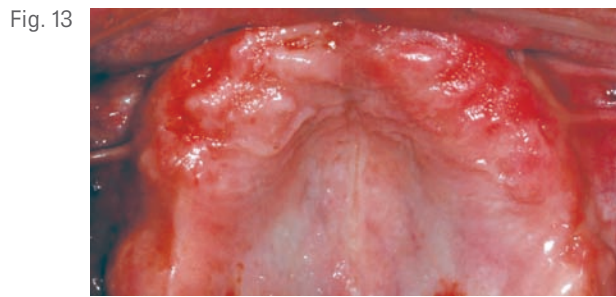
A mandibular surgical guide was fabricated as a duplicate of the mandibular immediate denture. The surgical guide was tried in. An alveolectomy was accomplished consistent with the known surgical volume required for implant primary stability (Fig. 5). One NanoTite™ Tapered PREVAIL® Implant and four NanoTite Tapered Implants were placed consistent with the treatment plan in tooth positions 20, 22, 25, 27, and 29 [35, 33, 41, 43 and 45]. The two posterior implants were placed with a distal tilt. This increased the AP spread. The distal tilts of the posterior implants were compensated with 30 degree



Angled Low Profile Abutments. Since no angle correction was needed for the three anterior implants, straight Low Profile Abutments with 2mm collar heights were selected (Fig. 6). Due to the minimal restorative volume in the mandible, Low Profile Abutments were used to minimize the amount of restorative volume occupied by the implant abutments. Figure 7 shows the dimensions and configurations of Low Profile Abutments. All abutment screws were torqued to 20Ncm with a torque indicating device.

Quick-setting polyvinylsiloxane occlusal registration material was injected into the intaglio surface of the immediate denture and the prosthesis was inserted with the patient in centric occlusion. The locations of the

implants were identified in the impression (Fig. 8). Holes were drilled through the denture to facilitate attachment of the temporary cylinders to the prosthesis. Low Profile Abutment Non-Hexed Temporary Cylinders were placed onto the abutments (Fig.9); their heights were adjusted extraorally so that these fit within the confines of the occlusal surfaces of the denture teeth and did not interfere with the vertical dimension of occlusion. A rubber dam was placed around the mandibular abutments and cylinders (Fig 10). This isolated the surgical and prosthetic fields. The mandibular prosthesis was adjusted to provide clearance for the temporary cylinders. The immediate mandibular denture was converted into a fixed provisional restoration by injecting autopolymerizing acrylic resin into the intaglio surface of



the prosthesis and around the temporary cylinders. The patient was guided into centric occlusion and the resin was allowed to set. The prosthesis was removed by unscrewing the retaining screws.

Polishing protectors were placed onto the abutment restorative platforms of the cylinders and the prosthesis was finished and polished. It was inserted back onto the Low Profile Abutments with the retaining screws (torqued to 10Ncm). The screw access openings were restored with light cured composite resin.

The patient left the surgical office with an immediate maxillary complete denture and a mandibular fixed-provisional implant-retained prosthesis in place (Figs. 11

and 12). The mandibular prosthesis was supported by five implants. Each implant had an insertional torque of at least 50Ncm and was considered primarily stable. The vertical dimension of occlusion was not changed from the patient's original presentation. He was discharged in excellent condition and was scheduled to return in 10 days for the first post-operative visit.

Phase II Treatment

Two months post-phase I treatment, the patient returned for phase II treatment. This included placement of six maxillary implants, immediately followed by conversion of the pre-existing complete denture to a fixed, implant-retained prosthesis, following the DIEM®2 Guidelines.

Fig. 19

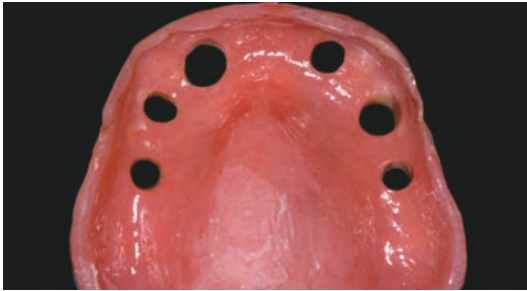

Fig. 20

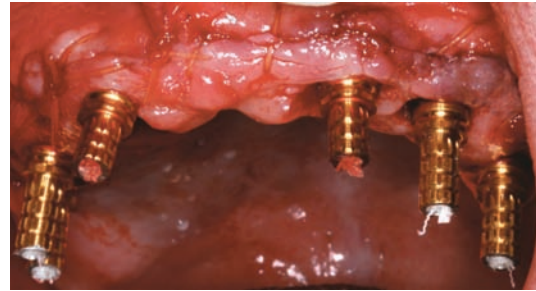


Fig. 21

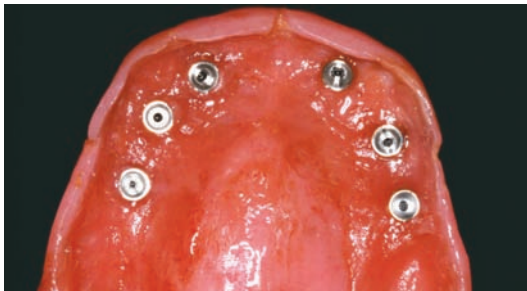

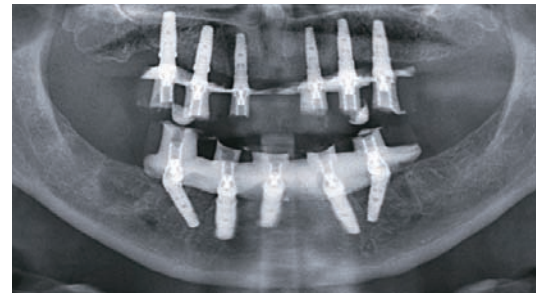
Fig. 22

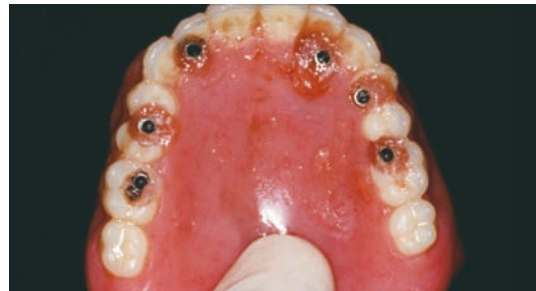

Fig. 23

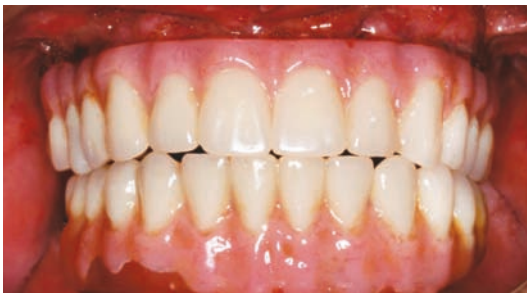

Fig. 24



The edentulous maxilla healed with a broad, U-shaped ridge and had adequate fixed, keratinized tissues (Fig. 13). The surgical guide that was previously made by duplicating the maxillary complete denture in clear acrylic resin was seated with a laboratory-fabricated interocclusal record (Fig. 14). A full thickness flap with a vestibular incision was reflected (Fig. 15). Four NanoTite™ Certain® Tapered Implants and two NanoTite Tapered PREVAIL® Implants were placed, each with insertional torque values of at least 50Ncm. Straight collar One-Piece Low Profile Abutments (2mm and 3mm heights) were placed into the internal interface of the implants; secured with abutment screws, which were tightened to 20Ncm of torque using the Standard Abutment Driver Tip (RASA3) and a torque device (Fig. 16). A quick setting

polyvinylsiloxane occlusal registration material was injected into the intaglio surface of the maxillary denture (Fig. 17). The denture was placed into the mouth with the occlusal record to guide the patient into centric occlusion (Fig. 18). The material was allowed to set and the denture was removed. The locations of the implants relative to the denture teeth were identified. Holes were drilled through the prosthesis and the prosthesis was set aside (Fig. 19).

Low Profile Abutment Non-Hexed Temporary Cylinders were placed onto the abutments with retaining screws. These were hand tightened and the cylinders were adjusted extraorally and placed back onto the abutments (Fig. 20). The prosthesis was adjusted so that there was no

Brent R. Boyse, DDS and Sheldon Sullivan, DDS (continued)

contact with the temporary cylinders. A rubber dam was placed around the temporary cylinders that separated the surgical and prosthetic fields. The same autopolymerizing resin was used as described for the fabrication of the mandibular prosthesis. The pre-existing vertical dimension of occlusion was maintained during this portion of the procedure. The prosthesis was removed by releasing the retaining screws (Figs. 21 and 22). Polishing protectors were placed onto the abutment restorative platforms and the prosthesis was finished and polished.

The patient left the surgical office with a fixed maxillary implant retained prosthesis (Figs. 23 and 24). The mandibular fixed implant prosthesis remained in place. The mandibular prosthesis was supported by five implants; the maxillary prosthesis was supported by six implants. At the time of initial implant placement, each implant had an insertion torque of at least 50Ncm and was considered primarily stable. The vertical dimension of occlusion was not changed from the patient's original presentation. He was discharged in excellent condition and was scheduled to return in 10 days for the first post-operative visit.

Clinical Relevance

The complex treatment described here is a perfect example of the cooperation necessary among the dental implant team, which in this case consisted of a surgeon, restorative dentist, and dental laboratory technician. The implants were first placed in the mandible. Traditionally mandibular bone is denser than maxillary bone; implants placed typically have insertion torques in excess of 50Ncm. This patient's pre-operative maxilla did not have adequate bone for immediate implant placement post-extraction. Bone grafting (bilateral sinus lifts) was needed in the posterior segments. After osseous healing, the maxillary bone was dense enough to provide implant primary stability at the time of implant placement. The

maxillary implants achieved insertion torques similar to those achieved for the mandibular implants. The maxillary complete denture was converted into a fixed, implant-retained prosthesis using the same protocol as the mandibular prosthesis. Although the placement of four rigidly splinted implants has been shown in the literature to be highly successful, the requirements for each patient must be carefully evaluated. Several factors need to be considered when treatment-planning these complex cases, including bone quality and quantity, AP spread, occlusal function of the patient, and skeletal pattern.

For more information about BIOMET 3i Low Profile Abutments, please contact your local BIOMET 3i Sales Representative today.

**The contributing clinicians have financial relationships with BIOMET 3i LLC resulting from speaking engagements, consulting engagements and other retained services.*

Brent R. Boyse, DDS



Dr. Boyse received his dental degree from the University of the Pacific, Arthur A. Dugoni School of Dentistry where he was inducted into the Omicron Kappa Upsilon Honor Society. He completed his Oral and Maxillofacial Surgery residency at the University of Rochester in Rochester, New York. He is Board Certified through the American Board of Oral and Maxillofacial Surgery. Dr. Boyse maintains a group practice in Mesa, Arizona.

Sheldon Sullivan, DDS



Dr. Sullivan graduated from University of the Pacific, Arthur A. Dugoni School of Dentistry. He has completed hands-on curriculum with some of dentistry's leaders in aesthetic and restorative procedures including the Spear Institute, KOIS Center for Dental Excellence and the Pacific Aesthetic Continuum. He currently serves as a lead mentor for the Spear Education Live Patient Programs. He is a Fellow of the Academy of General Dentistry. Dr. Sullivan maintains a private general practice with an emphasis on implant, restorative and aesthetic dentistry in Mesa, Arizona.



ART 1142
REV A 05/11